Surg Endosc (2012) 26:2988–2992
DOI 10.1007/s00464-012-2296-2

# The lateral decubitus position improves transoral endoscopic access to the posterior aspects of the thorax

**Chen Yang · Yen Chu · Yi-Cheng Wu · Ming-Ju Hsieh · Ming-Shian Lu · Chieng-Ying Liu · Hsu-Chia Yuan · Yun-Hen Liu · Po-Jen Ko · Hui-Ping Liu**

Received: 5 July 2011 / Accepted: 2 April 2012 / Published online: 2 May 2012


**Abstract**
*Background* The success of natural orifice transluminal endoscopic surgery (NOTES) depends on an adequate exploration of surgical regions. Currently, limited data are available regarding the optimal position for the NOTES approach for thoracic surgery. This study therefore aimed to evaluate the effectiveness of transoral thoracic exploration in a canine model placed in a lateral decubitus position.
*Methods* A total of 14 dogs were used in this study. Transoral thoracoscopy was performed using a custom-made metal tube via an incision over the vestibular incision with the animal in a supine position. After thoracic exploration, the animal was placed in a lateral decubitus position. The thoracic intervention (surgical lung biopsy, pericardial window creation, and dorsal sympathectomy) was performed by passing a flexible bronchoscope through the lumen of a metal tube.
*Results* The mean operative time for this procedure was 70 min (range 45–100 min). For 12 dogs, all procedures were completed without major complications. However, for one dog, the exploration of the thoracic cavity was incorrect (the right lower lobe had been misinterpreted as the left lower lobe). Another dog had minor bleeding because of an intercostal artery injury that occurred during sympathectomy.
*Conclusion* The posterior aspect of the thoracic cavity can be exposed via a transoral approach with the animal in a lateral decubitus position. This approach may be considered as an adjuvant to the supine approach, in which exploration of the posterior thoracic cavity is restricted.

**Keywords** Surgical lung biopsy · Transoral thoracoscopy

**Electronic supplementary material** The online version of this article (doi:10.1007/s00464-012-2296-2) contains supplementary material, which is available to authorized users.

C. Yang
Division of Genetics, Department of Pediatrics, Taipei Medical University Hospital, Taipei, Taiwan, ROC

Y. Chu · Y.-C. Wu · M.-J. Hsieh · H.-C. Yuan · Y.-H. Liu (✉) · P.-J. Ko
Laboratory Animal Center, Department of Surgery, Chang Gung Memorial Hospital, Linko, Chang Gung University, No. 5, Fu-Shing Street, Guei-Shan Shiang, Tao-Yuan 333, Taiwan, ROC
e-mail: zebraairmail@gmail.com; foreverairmail@gmail.com

M.-S. Lu
Department of Surgery, Chang Gung Memorial Hospital, Chayi, Chang Gung University, Tao-Yuan 333, Taiwan, ROC

C.-Y. Liu
Department of Medicine, Chang Gung Memorial Hospital, Linko, Chang Gung University, Tao-Yuan 333, Taiwan, ROC

H.-P. Liu
Department of Surgery, Benq Medical Center, Nanjing, China

Natural orifice transluminal endoscopic surgery (NOTES) is a relatively new technique for accessing the thoracic and abdominal cavities. The potential benefits of this technique include quick recovery, a short hospital stay, no requirement of a skin incision, and less postoperative pain [1]. The various approaches for accessing the thoracic cavity that have proved to be feasible in animal models include transvesical, transesophageal, transgastric, and transtracheal routes. However, none of these approaches are considered ideal due to the risk of several complications such as tension pneumothorax, bleeding, and mediastinitis [2–5].

In a previous study, we reported the feasibility and safety of transoral surgical lung biopsy and pericardial

window creation in dogs. In that study, we found that the posterior pleural cavity and posterior mediastinum were not sufficiently exposed when the dogs were kept in a supine position. Hence, in this study, we used the transoral approach to access the thoracic cavity of 14 dogs placed in a lateral decubitus position.

## Methods

For this experiment, 14 dogs weighing 7.6–9.4 kg were used. The study was approved by the Ethics Committee on Animal Research of the Chang Gung Memorial Hospital. The dogs were placed in the supine position, and anesthesia was induced with ketamine (5 mg/kg) and xylazine HCl (10 mg/kg). A homemade long endotracheal tube was introduced into the main bronchus, with the proximal end of the cuff located just below the tracheal carina. General anesthesia was induced and maintained throughout the surgery by isoflurane (2–5 %) inhalation.

After the animal had been positioned in either a lateral decubitus ($n = 1$) or a supine ($n = 13$) position, the left thoracic cavity was approached through a right vestibular incision in dogs 1–8 and through the right thoracic cavity via a left vestibular incision in dogs 9–14. To enable safe thoracic access, a homemade metallic tube was used to create a working tract via the pretracheal and substernal planes in order to approach the thoracic cavity under endoscopic guidance.

After ventilation was discontinued and the lungs collapsed, the mediastinal pleura was punctured using the aforementioned blunt metallic tube, which then was advanced through the mediastinum for thoracic exploration. A flexible bronchoscope (Olympus Ltd., Tokyo, Japan) was passed through the metallic tube into the pleural cavity for complete exploration of the thoracic cavity including the lungs, mediastinum, pleural wall, and diaphragm.

The animals then were positioned in a lateral decubitus position with the operative side up. Thereafter, a minor thoracic procedure involving dorsal sympathectomy, endoscopic lung biopsy, and pericardial window creation was performed in all the animals. The lung biopsy was performed using the flexible bronchoscope, an endoscopic grasper (Olympus Ltd.), and an electrosurgical snare (Olympus Ltd.). The completeness of the resected lung margin was tested under positive ventilation. Endoloops were placed at the resection margin to minimize air leaks after lung biopsy, as previously described. A needleknife (Olympus Ltd.) was used to create the pericardial window and to perform dorsal sympathectomy.

The animals were killed 30 min after completion of the thoracic procedure by intravenous administration of xylocaine (200 mg). Necropsy was performed to evaluate the operative result and to detect any signs of intrathoracic complications.

## Results

The mean operative time was 70 min (range 45–100 min). The anterior and lateral aspects of the thoracic cavity and mediastinum were adequately accessible when the animals were kept in the supine position (Table 1). The posterior hemithorax was accessible only when the animals were placed in the lateral decubitus position. Complications were noted in one patient who had undergone a transoral approach to the thoracic cavity. The complications included inability to approach the pleural cavity because of failure to obtain the appropriate endoscopic orientation when the animal was placed in the lateral decubitus position, which led to an inadequate lung biopsy at the beginning of this study. To ensure that the correct pleural cavity was accessed, we approached the pleural cavity with the animal in a supine position. Therefore, we did not face any technical difficulties in the following experiment. Another dog had minor bleeding from the intercostal artery, which was injured during sympathectomy, and hemostasis was achieved using the needleknife.

Using the contralateral transoral approach, the middle and lower portions of the posterior hemithorax could be easily accessed without the need for further assistance. The thoracic sympathetic trunks were identified without difficulty, and complete sympathectomy was successfully performed in 12 dogs by using the direct en face view. Despite multiple attempts in two of the animals, complete sympathectomy failed because the "straight" needleknife could not be advanced to the sympathetic nerve trunk.

In 13 dogs, the predetermined biopsy lung region was successfully resected using endoloop cautery. In the one animal, use of the lateral decubitus approach made it difficult to identify adequately the posterior border of the sternum and the anterior mediastinal border, thus resulting in incorrect access to the pleural space. This led to wrong-site surgical lung biopsy, with resection of the right lower lobe instead of the left lower lobe. Endoloops were placed at the resected lung margin in one animal. No air leaks were noted in any of the animals after the surgical lung biopsy.

Creation of the pericardial window, either anterior or posterior to the phrenic nerve, was completed in all the animals. The pericardial cavity was successfully examined via the pericardial window by using the flexible bronchoscope.

All the animals survived the surgery and were killed 30 min after creation of the pericardial window. Necropsy confirmed that the lung biopsy, pericardial window creation, and bilateral dorsal sympathectomy had been successfully performed, as previously described. No evidence of injury to

**Table 1** Procedure characteristics and animal outcomes

| Animal | Duration (min) | Body weight (kg) | Side of oral incision | Thoracic procedures | | | Complication | Necropsy finding |
|---|---|---|---|---|---|---|---|---|
| | | | | Target region of surgical lung biopsy | Success of pericardial window creation | Level of sympathe-ectomy | | |
| Dog 1 | 45 | 9.4 | Right | LLL | Yes | No | Failure to approach the thoracic cavity | Incorrect lung biopsy (RLL) |
| Dog 2 | 75 | 8.3 | Right | LLL | Yes | Lower (level 1) | No | Success of thoracic procedures |
| Dog 3 | 80 | 9.3 | Right | LLL | Yes | Lower (level 2) | No | Success of thoracic procedures |
| Dog 4 | 87 | 9.3 | Right | LLL | Yes | Lower (level 2) | No | Success of thoracic procedures |
| Dog 5 | 70 | 8.6 | Right | LUL | Yes | Lower (level 1) | No | Success of thoracic procedures |
| Dog 6 | 70 | 9 | Right | LUL | Yes | Lower (level 1) | No | Success of thoracic procedures |
| Dog 7 | 68 | 9.4 | Right | LUL | Yes | No | Intercostal artery injury | Intercostal artery injury |
| Dog 8 | 75 | 8.7 | Right | LUL | Yes | Lower (level 2) | No | Success of thoracic procedures |
| Dog 9 | 50 | 8.2 | Left | RLL | Yes | Lower (level 3) | No | Success of thoracic procedures |
| Dog 10 | 80 | 8.2 | Left | RLL | Yes | Lower (level 1) | No | Success of thoracic procedures |
| Dog 11 | 65 | 8.3 | Left | RLL | Yes | Lower (level 3) | No | Success of thoracic procedures |
| Dog 12 | 65 | 7.7 | Left | RUL | Yes | Lower (level 1) | No | Success of thoracic procedures |
| Dog 13 | 52 | 8.1 | Left | RUL | Yes | Lower and middle (level 4) | No | Success of thoracic procedures |
| Dog 14 | 100 | 7.6 | Left | RUL (1 loop) | Yes | Lower and middle (level 6) | No | Success of thoracic procedures |

*LLL* left lower lobe; *RLL* right lower lobe; *LUL* left upper lobe; *RUL* right upper lobe

the thoracic entrance, mediastinum, or thorax was noted in any of the animals (Fig. 1; Video 1a, b; Video 2a, b).

## Discussion

Previous studies have reported the success of NOTES in accessing the thoracic cavity in animals. Such novel approaches allow physicians to access the thoracic cavity via natural orifices without incising the skin [2–5].

The first method reported for thoracic exploration and peripheral lung biopsy involved a combination of transvesical and transdiaphragmatic approaches. However, access to the upper thorax via the vesicle is difficult due to the inadequate length of the rigid instruments used. Consequently, this technique is less preferred [2].

The transesophageal approach also has been widely reported for assessment of the pleural cavity on both sides. However, meticulous training is required before a surgeon can perform this intervention over the upper mediastinum under retroflexed endoscopic visualization. In addition, this procedure has the risk of intraoperative complications such as aorta injury, tension pneumothorax, and difficulty determining the exact location of the pleura (the left or right pleural cavity) [3].

De Palma et al. [4] reported a novel approach for thoracic exploration via a transgastric route, but this technique has the risk of gastric wound disruption. Furthermore, we believe that the less complex a technique is, the less time and effort are required to make it popular. Moreover, the use of a gastric incision in NOTES for access to the upper mediastinum is difficult because the required working distance is considerably long.

More recently, we have described the successful use of the transtracheal route for thoracic exploration in both canine and porcine models. However, because of potential life-threatening complications associated with this procedure, such as tension pneumothorax and massive bleeding due to hilar injury, further preclinical studies of this procedure currently have been delayed [5].

Initially, with our transoral approach for accessing the thoracic cavity by keeping the animals in the supine position, we could successfully explore the right and left pleural cavities and perform lung biopsy over the anterior aspect of the thorax. However, adequate access to the paravertebral and posterior aspects of the thorax was restricted due to the supine placement of the animals. By simply changing the position of the canine subjects from supine to lateral decubitus, we could explore the posterior

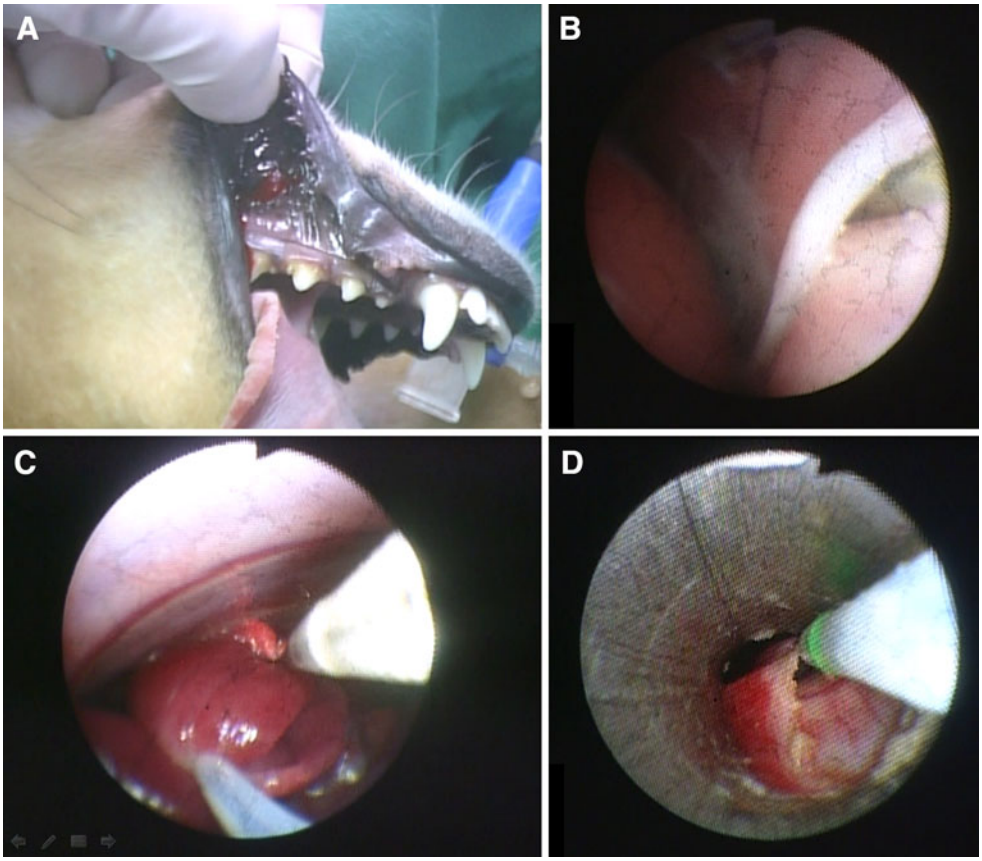


**Fig. 1** **A** Vestibular incision for a transoral approach to the thoracic cavity. **B** Dorsal sympathectomy performed using a needleknife. **C** Surgical lung biopsy performed with an electrocautery loop window. **D** Pericardial window creation with a needleknife

aspect of the thorax and even perform bilateral dorsal sympathectomy using current endoscopic methods.

One of the most important considerations in the performance of NOTES is exploration of the surgical region. Published reports describing the use of intermittent apnea for thoracoscopic approaches state that the endoscopic procedure is more technically demanding and associated with the risk of fetal hypoxia [6]. Another report suggests that the use of positive-pressure insufflation in thoracoscopy could cause hemodynamic compromise [7].

In the current study, adequate lung collapse on the operative side was achieved by simply placing the cuff of the homemade tracheal tube in the contralateral mainstem bronchus. This maneuver provides surgical access to the operative region, with maintenance of adequate oxygenation and ventilation. This has become the standard technique for anesthesia in our study of transoral NOTES.

Several studies reported in the literature discuss the potential perioperative complications of NOTES. These complications include massive bleeding, vital organ injury, and infection of the intrathoracic cavity infection.

In the current study, we did not observe any of the major complications reported in the literature, except for a case of bleeding after intercostal artery bleeding. No vital organ injury was observed in our study. This can be attributed to the optimization of the technique to perform NOTES and extensive experience using this procedure.

Furthermore, in our study, the incidence of complications was low because of the transoral approach, which obviated the need for viscerotomy closure. This indicates that the transoral approach may be an effective and safe platform for performing NOTES.

This study had some limitations [1]. The sample in this study was relatively small, and the study involved non-survival canine models. Studies with a large number of survival animal models are necessary before this technique can be used clinically [2].

We were able to introduce the metal tube into the thoracic cavity without difficulty. This may be attributable to the experience of the investigator in transoral thoracoscopy and the anatomy of dogs (a dog's neck is long and allows sufficient space for transoral thoracoscopy). However, the anatomies of dogs and humans differ, and we think that the transoral approach may be feasible in humans who are thin and have long necks but not in obese patients with thick or short necks [3].

With the current use of the straight needleknife, sympathectomy would be a technically demanding procedure,

and better endoscopic instrumentation, such as a curved needleknife, may provide an efficient approach to further exploration of the sympathetic chain and allow the surgeon to perform sympathectomy without difficulty [4]. Large lesions (>1 cm) may not be removable through the metallic tube. Thus, the technique should be used only for diagnosis, simple thoracic interventions, and removal of small tumors.

In conclusion, endoscopic access to the thoracic cavity via the transoral route with the animal in the lateral decubitus position is a simple, practical, and feasible method for performing surgical lung biopsy, pericardial window creation, and bilateral dorsal sympathectomy. We believe that good exposure to the posterior aspect of the thorax is not obtained when the animal is in the supine position. This difficulty can be overcome by the placing the animal in the lateral decubitus position.

Considering the encouraging results of this study, we currently have initiated an institutional review board (IRB)-approved study on performing basic thoracic procedures such as surgical lung biopsies and creation of pericardial window through the transoral approach in human cadaveric subjects. Furthermore, we plan to perform human preclinical studies on this novel approach after obtaining IRB approval.

**Acknowledgments** This work was supported by the Chang-Gung Memorial Hospital, Taiwan (Contract no. CMRPG 391911).

**Disclosures** Chen Yang, Yen-Chu, Yi-Cheng Wu, Ming-Ju Hsieh, Ming-Shian Lu, Chieng-Ying Liu, Hsu-Chia Yuan, Yun-Hen Liu, Po-Jen Ko, and Hui-Ping Liu have no conflicts of interest or financial ties to disclose.

## References

1. Bergman S, Melvin WS (2008) Natural orifice translumenal endoscopic surgery. Surg Clin North Am 88:1131–1148
2. Lima E, Henriques-Coelho T, Rolanda C, Pêgo JM, Silva D, Carvalho JL, Correia-Pinto J (2007) Transvesical thoracoscopy: a natural orifice translumenal endoscopic approach for thoracic surgery. Surg Endosc 21:854–858
3. Willingham FF, Gee DW, Lauwers GY, Brugge WR, Rattner DW (2008) Natural orifice transesophageal mediastinoscopy and thoracoscopy. Surg Endosc 22:1042–1047
4. De Palma GD, Siciliano S, Addeo P, Salvatori F, Persico M, Masone S, Rega M, Maione F, Coppola EB, Serrao E, Adamo M, Persico G (2010) A NOTES approach for thoracic surgery: transgastric thoracoscopy via a diaphragmatic incision in a survival porcine model. Minerva Chir 65:11–15
5. Liu YH, Chu Y, Liu CY, Liu HP, Wu YC, Hsieh MJ, Liu HP (2011) Feasibility of the transtracheal approach for the thoracic cavity in a large animal model. Surg Endosc 25:1652–1658
6. Mouroux J, Clary-Meinesz C, Padovani B, Perrin C, Rotomondo C, Chavaillon JM, Blaive B, Richelme H (1997) Efficacy and safety of videothoracoscopic lung biopsy in the diagnosis of interstitial lung disease. Eur J Cardiothorac Surg 11(22–24):25–26
7. Hill RC, Jones DR, Vance RA, Kalantarian B (1996) Selective lung ventilation during thoracoscopy: effects of insufflation on hemodynamics. Ann Thorac Surg 61:945–948